

Decedent is
RESIDENT
of City/ County of Death

Commonwealth of Virginia
Department of Health
Office of the Chief Medical Examiner
CENTRAL DISTRICT
400 EAST JACKSON STREET RICHMOND, VA 23219

Case Number:
C2017-64645

REPORT OF INVESTIGATION

Decedent HEATHER DANIELLE HEYER
First Name Middle Name Last Name Suffix Sr, Jr, III, etc
SSN 227-35-0547

Home Address 1224 PRESTON AVENUE APT# A CHARLOTTESVILLE, VA 22903
Number and Street City, State, Zip

Age 32 Yrs DOB 5/29/1985 Sex FEMALE Last Known Occupation PARALEGAL

Race WHITE Hispanic? NO Marital Status NEVER MARRIED

MEDICAL EXAMINER AUTHORITY VIOLENT OR UNNATURAL

Police Notified YES Investigator DETECTIVE CARPER Phone (434) 970-3280 Jurisdiction CHARLOTTESVILLE

	DATE (MM/DD/YY)	TIME (24h)	LOCATION	CITY/ COUNTY	BY WHOM
LAST KNOWN ALIVE	8/12/2017	1346	100 4TH STREET AT WATER STREET	CHARLOTTESVILLE CITY, VA	BYSTANDERS
EVENT/ INJURY ACUTE ILLNESS	8/12/2017	1346	100 4TH STREET AT WATER STREET	CHARLOTTESVILLE CITY, VA	BYSTANDERS
FOUND	8/12/2017	1346	100 4TH STREET AT WATER STREET	CHARLOTTESVILLE CITY, VA	BYSTANDERS
DEATH/ PRONOUNCED	8/12/2017	1422	UVA MEDICAL CENTER	CHARLOTTESVILLE CITY, VA	ER DOCTOR
EXAMINATION OF BODY	8/14/2017	1100	400 EAST JACKSON STREET	RICHMOND CITY, VA	BOWERS, JENNIFER

Cause of Death:
BLUNT FORCE INJURY TO TORSO

Manner of Death: **HOMICIDE**

Autopsy (Y/N):	Y
Authorized by	ASSISTANT CHIEF MEDICAL EXAMINER
Pathologist	BOWERS, JENNIFER
Autopsy No	C0529-17
Location	CENTRAL OCME

This case was reviewed by:

30-Oct-2017 1242
Date/Time

JENNIFER BOWERS
Name of Assistant Chief Medical Examiner

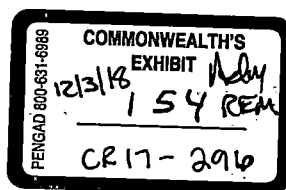
Jennifer Bowers MD
Signature of Assistant Chief Medical Examiner

30-Oct-2017 1125
Date/Time

BAILEY, SANISHA
Name of Reviewing Medicolegal Death Investigator

A COPY TESTE: 11/9/17

Samantha D. H. [Signature]
Assistant Chief Medical Examiner



MEDICAL HISTORY

- none known alcoholism cirrhosis hepatitis drug abuse asthma bronchitis emphysema
- seizure disorder (cause) _____ cancer _____ diabetes hypertension atherosclerosis
- stroke psychiatric diagnosis (specify) _____ depression dementia (specify) _____
- recent trauma (specify) _____ hip fracture
- acute infections (specify) _____ HIV/AIDS COPD obesity tobacco
- other (specify): _____

Treating MD _____ Phone# _____

Hospitalizations (when/where)

Medications

Tox requested: YES

Summary of Circumstances:

Per report, the decedent was a 32 year old white female pedestrian who was struck by a car. The driver of the vehicle did not remain at the scene and the decedent was rushed to the hospital. She was pronounced shortly after her arrival. Her death was reported to the OCME and she was transported to district office for autopsy examination.

Decedent: HEATHER DANIELLE HEYER

DEPARTMENT OF HEALTH
OFFICE OF THE CHIEF MEDICAL EXAMINER
400 EAST JACKSON STREET
RICHMOND, VIRGINIA 23219

Autopsy C0529-17
File # C2017-64645
Date / Time 8/14/17-Monday 11:00 AM

REPORT OF AUTOPSY

DECEDENT: Heather

Heyer

AUTOPSY AUTHORIZED BY: Dr. Jennifer Bowers, M.E. for Charlottesville City

BODY IDENTIFIED BY:

PERSONS PRESENT AT AUTOPSY:

Fingerprint examination by Department of
Forensic Science

Det. Hickey and Det. Carper of Charlottesville P.D. and A.
Rowshan

Rigor: Passing Livor: Purple Distribution: Posterior Age: 32 yrs Race: White
Sex: Female Length: ~ 59 in Weight: ~ 330 lbs Eyes: Hazel Hair: Brown
Mustache: NA Beard: NA Circumcised: NA Body Heat: Ambient

CLOTHING AND PERSONAL EFFECTS: The decedent is received with 1 pair of socks and clothing that has been previously cut: bra, underwear, and T-shirt. The decedent's shoes are not received. Personal effects: 3 hair ties, one pair of earrings, driver's license, and credit card. All clothing and personal effects have been submitted as evidence.

GENERAL EXTERNAL EXAMINATION: The decedent is a well-developed, well-nourished, obese white female. Injuries to the head, torso, and upper and lower extremities are listed in Pathological Diagnoses. The oral cavity, external nares, and external auditory canals are free of foreign material. The external and mucosal aspects of the lips are without injury. The neck is symmetrical with a range of mobility within normal limits. Aside from injury, the torso is symmetrical. The hands are received unbagged and remarkable for blood deposition bilaterally. The upper and lower extremities are symmetrical (aside from injury) and well developed.

MARKS OF THERAPY: Chest decompression catheters, endotracheal tube, EKG leads of the torso, single lumen catheter of the right arm, and intraosseous catheter of the calves bilaterally. A thoracotomy incision is identified along the left side of the chest, along the intercostal space below the left sixth rib. A chest tube is identified along the right side within the intercostal space below the right fifth rib.

MARKS OF ORGAN DONATION: None present.

SCARS: None grossly identifiable.

TATTOOS: Tattoos as per autopsy photos.

RADIOLOGY: Full skeletal survey reveals fracture of the right femur.

HISTORY: White female pedestrian struck by vehicle.

PATHOLOGICAL DIAGNOSES:

1. **Blunt force injury to head:**

- Nasal fracture with overlying contusion.
- Contusions of the face and left ear, up to 1 ½ inches.
- No evidence of skull fractures or intracranial hemorrhage.

2. **Blunt force injury to torso:**

- Complete transection of the thoracic aorta with surrounding hematoma.
- Anterior-lateral fractures of right ribs 1-8.
- Anterior-lateral fractures of left ribs 1-4.
- Bilateral pulmonary contusions and lacerations.
- Multifocal hepatic lacerations.
- Approximately 50 cc of blood recovered from the right and left pleural cavities.
- Mesenteric contusions.
- Contusions to the chest, back, and abdomen, ranging from punctate (1/16 inch) to greater than 5 inches.
- Abrasions to the chest, back, and abdomen, ranging from ¼ inch to greater than 6 inches.

Additional injuries, pathological diagnoses, and toxicology analysis continued on page 2.

Cause of Death: Blunt force injury to torso

Final Report: 10/30/2017

The facts stated herein are true and correct to the best of my knowledge and belief.

10/30/17
Date Signed

Richmond City
Place of Autopsy

COPY TESTE: 11/9/17

Jennifer Bowers M.D.
Signature of Pathologist
Jennifer Bowers, M.D.

James D. Shobley, M.D.
Assistant Chief Medical Examiner

3. **Blunt force injury to upper and lower extremities:**
 - a. Distal right femur fracture, 17 ¼ inches from the fracture to the heel (without shoes, not received).
 - b. Linear lacerations to the upper thighs and buttocks, extending to the subcutaneous adipose tissue, ranging between 1 inch to 11 inches.
 - c. Abrasions of the upper and lower extremities, ranging between ¼ inch to 2 inches
 - d. Contusions of the upper and lower extremities, ranging between ¼ inch to 7 inches.
4. **Additional pathological diagnoses:**
 - a. Macrovesicular steatosis, mild.
 - b. Cardiomegaly, mild.
 - c. Hemorrhagic ovarian cysts, up to 3.0 cm.
 - d. Leiomyoma.
 - e. Adhesions of the left lung and liver.
 - f. Obesity (BMI greater than 30).
2. **Postmortem toxicology (pooled blood):**
 - a. Tetrahydrocannabinol: 0.0021 mg/L.
 - b. THC Carboxylic Acid: 0.010 mg/L.
 - c. No other drugs and/or drug classes detected.
 - d. Drugs screened: ethanol, methanol, acetone, isopropanol, opiates, cocaine/benzoylecgonine, oxycodone/oxymorphone, methamphetamine/MDMA, phencyclidine, barbiturates, benzodiazepines, carisoprodol/meprobamate, fentanyl, methadone, cannabinoids, zolpidem, diphenhydramine/cyclobenzaprine, dextromethorphan, tramadol, tricyclic antidepressants, amphetamine/MDA/phentermine, and buprenorphine.

JB
10/30/17

GROSS DESCRIPTION

- SEROUS CAVITIES:** Bilateral hemothoraces as noted. The organs are in their usual anatomic locations.
- HEART:** The heart weighs 438 grams. The epicardial surface is glistening, smooth, and atraumatic. The coronary arteries arise and follow their usual distributions. The left and right main coronary arteries and their branches demonstrate mild atherosclerotic narrowing. The left ventricular wall is 10 mm in thickness, while the septum and right ventricle are 10 mm and 3 mm, respectively. The myocardium is red-brown and unremarkable. No evidence of acute hemorrhage or myocardial lesions present. Atrial and ventricular septae are intact. Valves are within normal limits.
- GREAT VESSELS:** The aorta is injured as described and exhibits minimal atherosclerosis; all major vascular ostia are grossly intact and probe patent. The inferior vena cava is grossly intact.
- NECK ORGANS:** Soft tissues and strap muscles of the neck are unremarkable and without evidence of injury. The hyoid bone and laryngeal cartilages are intact. The thyroid gland is unremarkable.
- LUNGS:** The right and left lungs weigh 502 grams and 464 grams respectively. The upper airways are free of froth and foreign material. The lungs are injured as described. Serial sections of the pulmonary parenchyma reveal minimal blood and frothy fluid exuded. The pulmonary arteries are patent, without thrombus or embolus.
- LYMPH NODES:** Within normal limits.
- LIVER:** 1436 grams. The liver is injured as described and covers a moderately congested, red-brown parenchyma. The cut surface exhibits no evidence of focal lesions, cirrhosis, or gross evidence of fatty change.
- GALLBLADDER:** Less than 20 cc of bile. Unremarkable mucosa with no evidence of stones.
- SPLEEN:** 246 grams. Intact capsule covering a moderately firm, unremarkable parenchyma.
- PANCREAS:** Yellow, lobulated cross-section.
- ADRENAL GLANDS:** Within normal limits.
- GI TRACT:** Tongue with no evidence of injury. Esophagus unremarkable. The stomach exhibits the usual rugal folds and contains 100 cc of liquid of homogeneous chyme. The small and large bowel are intact and unremarkable; mesenteric contusions as noted. The appendix is present.
- KIDNEYS:** The right and left kidneys weigh 146 grams and 142 grams respectively. The capsules strip easily to reveal regular, smooth contours. The renal parenchyma is red-brown with well-demarcated, corticomedullary junctions. The pelves and ureters are unremarkable without evidence of distension.
- BLADDER:** No urine available for collection. The mucosa is tan-pink and unremarkable.
- GENITALIA:** Sectioning of the ovaries reveals multiple hemorrhagic cysts, ranging between 1.0-3.0 cm. A single leiomyoma is identified upon opening the cervix and uterus. The internal genitalia are otherwise unremarkable and appropriate for age.
- BRAIN & MENINGES:** The brain weighs 1314 grams. The dura mater is intact. No evidence of epidural, subdural, and subarachnoid hemorrhages is present. The leptomeninges are thin and delicate. Serial coronal sections through the cerebral hemispheres demonstrate no evidence of intraparenchymal hemorrhage or focal lesions. The lateral ventricles are of the usual caliber. Serial transverse sections through the brainstem and cerebellum are unremarkable. Intraventricular hemorrhage is not present.
- MUSCULOSKELETAL:** Bilateral rib, right femur, and nasal fractures as described. Subgaleal hemorrhage is absent. Skull fractures are absent. Skeletal muscle is red-tan and moist with a mass appropriate for the decedent's age and sex.

MICROSCOPIC SECTIONS: Heart, lung, liver, kidney, aorta

OTHER LAB PROCEDURES: PHOTO Y MICRO Y TOX Y X-RAY Y FINGERPRINTS Y DENTAL N
DNA Y GSR N PERK N BACTERIOLOGY N VIROLOGY N ACCELERANTS N OTHER

DISPOSITION OF EVIDENCE:

TOXICOLOGY: Blood and vitreous.

OCME: Liver and bile.

INVESTIGATOR: Clothing, personal effects, buccal swab, and nail clippings.

FUNERAL HOME: Nothing submitted.

JB
10/20/17

MICROSCOPIC DESCRIPTION

- Aorta, slide 1: Disruption of the aorta is noted with hemorrhage extending from the tunica adventitia to the outer third of the tunica media.
- Heart, slide 2: Mild myocyte hypertrophy noted with perivascular and interstitial fibrosis. No evidence of hemorrhage, contraction band necrosis, or inflammation present.
- Liver and kidney, slide 3: The liver is autolyzed and demonstrates mild macrovesicular steatosis and unremarkable portal triads. Section of kidney with unremarkable glomerular, interstitial, and tubular components.
- Lungs, slide 4: Pulmonary parenchyma with foci of interstitial chronic inflammatory aggregates, an encapsulated, bronchocentric lymph node, and edema present; no other pathological abnormalities noted.

SUMMARY:

Per report, the decedent was a 32-year-old white woman within a crowd of pedestrians. She was struck by a vehicle that drove into the crowd. The driver of the vehicle did not remain at the scene. Several pedestrians were also injured during this incident. Due to life threatening injury, the decedent was rushed to the hospital by EMS. She died from her injuries shortly after her arrival to the emergency room. Her death was reported to the OCME and jurisdiction was accepted. She was transported to district office for autopsy examination.

Autopsy examination revealed blunt force injuries to the torso (chest and abdomen) consisting of: transection of the thoracic aorta, bilateral rib fractures, pulmonary contusions and lacerations, hepatic lacerations, and mesenteric contusions. Less than 50 cc of residual blood was recovered within the pleural cavities after medical interventions. Postmortem toxicology demonstrated cannabinoids.

The cause of death was due to blunt force injury to the torso. The manner of death was determined to be homicide based upon review of police investigation.

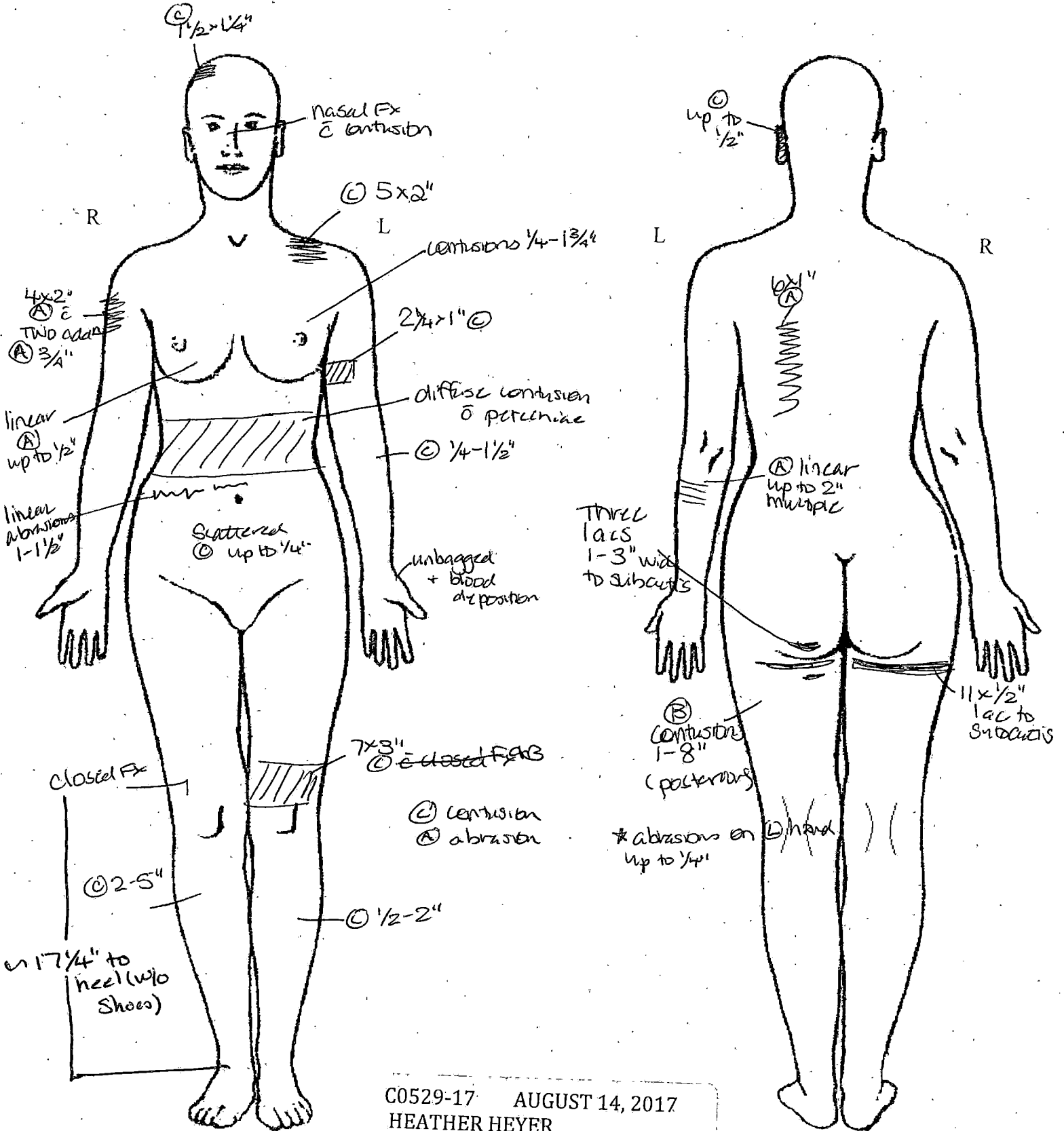
CAUSE OF DEATH:

Blunt force injury to torso

MANNER OF DEATH:

Homicide

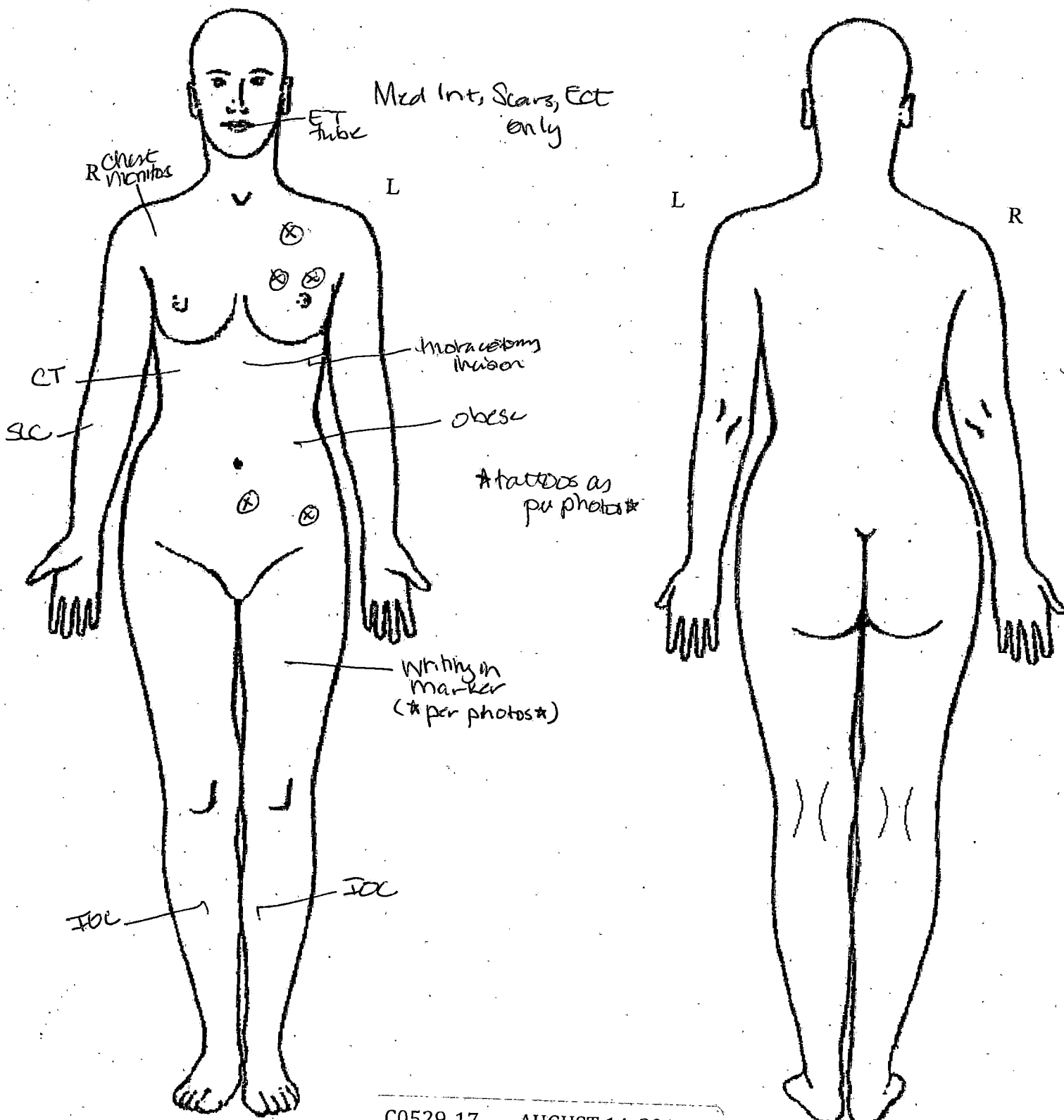
OKB
10/30/17



C0529-17 AUGUST 14, 2017
HEATHER HEYER
CHARLOTTESVILLE
C2017-64645

JB

NOT TO SCALE



C0529-17 AUGUST 14, 2017
HEATHER HEYER
CHARLOTTESVILLE
C2017-64645

JB



DEPARTMENT OF FORENSIC SCIENCE

CERTIFICATE OF ANALYSIS

Central Laboratory
700 N. 5th Street
Richmond, VA 23219

September 14, 2017

Tel. No.: (804) 786-4707
Fax: (804) 786-6907

TO: JENNIFER BOWERS, M.D.
OFFICE OF THE CHIEF MEDICAL EXAMINER
400 EAST JACKSON STREET
RICHMOND, VA 23219



FS Lab # C17-9729

RECEIVED
SEP 2017
OFFICE OF
CHIEF MEDICAL EXAMINER

Your Case #: C2017-64645, C0529-17

Victim(s): HEYER, Heather

Suspect(s): - - -

Evidence Submitted By: Scott Banning

Date Received: 08/15/2017

Item TX1 Two (2) red border vials of pooled blood
Item TX2 One (1) vial of vitreous

RESULTS:

Item TX1

Pooled Blood:

- Ethanol none detected
- Tetrahydrocannabinol 0.0021 mg/L
- THC Carboxylic Acid 0.010 mg/L
- No other drugs and/or drug classes were detected.

Item TX1 was screened for the following drugs and/or drug classes:

Ethanol, methanol, acetone, isopropanol, cocaine/benzoylcegonine, opiates, oxycodone/oxymorphone, methamphetamine/methylenedioxymethamphetamine (MDMA), phencyclidine, barbiturates, benzodiazepines, carisoprodol/meprobamate, fentanyl, methadone, cannabinoids, zolpidem, diphenhydramine/cyclobenzaprine, dextromethorphan, tramadol, tricyclic antidepressants, amphetamine/methylenedioxyamphetamine (MDA)/phentermine, buprenorphine.

Item TX2

Vitreous:

Not analyzed

See attached document for Uncertainty of Measurement reporting.

Supporting examination documentation is maintained in the case file. The evidence is being returned to the Office of the Chief Medical Examiner.

A COPY TESTE: 11/9/17

James D. Hollings
Assistant Chief Medical Examiner



Commonwealth of Virginia

ORIGINAL

DEPARTMENT OF FORENSIC SCIENCE

CERTIFICATE OF ANALYSIS

Office of the Chief Medical Examiner
FS Lab # C17-9729
Your Case # C2017-64645, C0529-17
September 14, 2017

Attest:

I certify that I performed the above analysis or examination as an employee of the Department of Forensic Science and that the above is an accurate record of the results and interpretations of that analysis or examination.

A handwritten signature in black ink, appearing to read "J. Yox".

Jennifer Yox
Forensic Scientist

JY

Handwritten initials "JYM" in black ink.



COMMONWEALTH of VIRGINIA
DEPARTMENT OF FORENSIC SCIENCE

Attachment: Uncertainty of Measurement (UoM)
FS Lab #: C17-9729

TX1 Tetrahydrocannabinol 0.0021 ± 0.0005 mg/L
THC Carboxylic Acid 0.010 ± 0.002 mg/L

Measurement uncertainty is reported at a 95.45% level of confidence for all toxicological analyses except blood, alcohol or ethanol which is reported at a 99.73% level of confidence.